

Activating healing naturally in three chronic ulcers using Hyaluronic Acid/Iodine Complex*

Rhian Parry-Ellis, Tissue Viability Nurse, Betsi Cadwaladr University Health Board

Background of clinical issues

Female patient, aged 67, with painful osteoarthritis exasperated by significant weight gain resulting in decreased mobility. Mrs X slept in a reclining chair, downstairs, for 12 months and presented with painful areas of broken skin to both buttocks.

Following GP referral and hospital admission for investigation and TV involvement, Mrs X was diagnosed with a Grade 4 sacral ulcer, a Grade 3 pressure ulcer to her inner right anal cleft and a Grade 2 pressure ulcer to the right buttock.

Following discharge home, Mrs X remained under the supervision of the Plastic Surgeon.

Management Approach

- Changes were made to relieve pressure from the wound sites.
- Following bariatric assessment and completion of an AIR Report, a profiling bed with pressure-relieving airwave mattress and pressure-relieving chair cushion, were prescribed. Mrs X did not quite meet bariatric criteria.
- Dietary changes were introduced and high protein drinks were prescribed.
- Analgesia was reviewed to help maintain concordance with the dressing regime.
- District nurses visited daily during winter 2010 and throughout 2011 to dress the wounds.

The wounds were kept clean, hydrated and free from infection but despite considerable weight loss and improved compliance, Mrs X became discouraged as the wounds failed to heal. Something was needed to regenerate and rebuild the damaged tissue.

In September 2011 the TVN recommended a hyaluronic acid & iodine complex which could be applied to a carrier dressing in this case, gauze and hydrofibre. Hyaluronic acid, natural to the body, plays a key role in tissue repair. The iodine inclusion prevents the hyaluronic acid from degrading. Permission to use this was granted by Mrs X's Consultant and GP.

Fig 1.

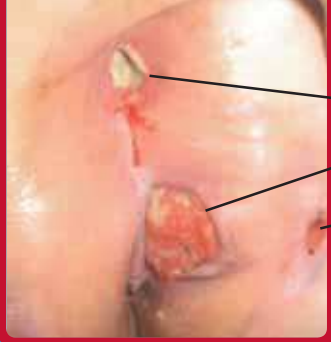

Fig 1. December 2010.
10 months before
Hyaluronic complex use
began
Grade 4 sacral pressure
ulcer.
Grade 3 sloughy pressure
ulcer. Right anal cleft.
Grade 2 pressure ulcer.
Right buttock.

Fig 2. November 2011
2 months after Hyaluronic
complex use began

Sacrum
Wound size: 1.5cm x 0.5cm
Right side of anal cleft.
Wound Size: 3.5cm x 2cm

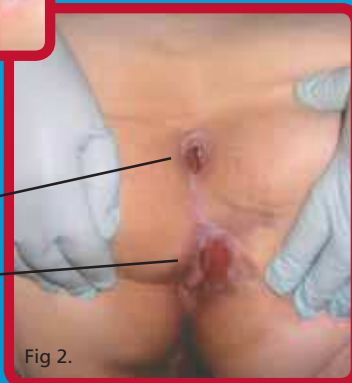


Fig 2.

Fig 3. March 2012

6 months of Hyaluronic complex
dressings anal cleft and right
buttock wounds completely healed.

Fig 3.

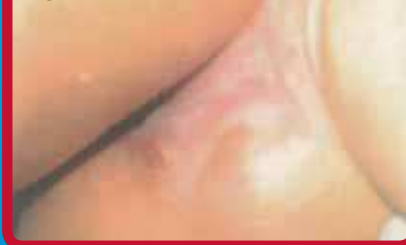

Fig 4.

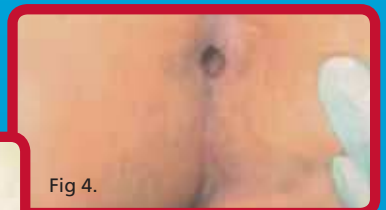

Fig 4. March 2012

The final 0.5cm of this cavity
won't heal. The patient appears
to be having non-related
health problems which could be
preventing this.

Outcomes

- Both Grade 2 & 3 ulcers healed completely within 3 months.
- Sacral wound, previously down to the bone, has 0.5cm to reach complete healing.
- No allergic reactions were experienced by the patient.
- The patient remained compliant throughout the treatment.

Conclusions

Never give up hope that wounds will heal unless the body is clearly incapable of supporting this function. Boosting the levels of hyaluronic acid, produced naturally by the body, encouraged granulation and epithelialisation to take place and these wounds to heal.

Highly professional and conscientious nursing from the District Nursing Team, working under the recommendations of the TVNs, combined with clinical innovation, restored Mrs X's dignity and improved her quality of life.