

COMPLEX APPROACH TO THE TREATMENT OF DIABETIC FOOT DEFECTS

Luboš Sobotka¹, Vladimír Velebný², Alena Šmahelová¹, Marie Kusalová¹, Jitka Stárková¹, Leontýna Voráčková¹
¹Department of Metabolic Care and Gerontology, Medical Faculty, Charles University, 500 05 Hradec Králové
²Contipro Biotech, Dolní Dobrouč, Czech Republic

INTRODUCTION

Diabetic ulcerations result from multiple factors such as microvascular defects, polyneuropathy, arterial occlusions and microbial contamination. The treatment of such defects is complex and based on the management of all aetiological factors. Here we present our results from the Foot Care Unit in our Faculty Hospital.

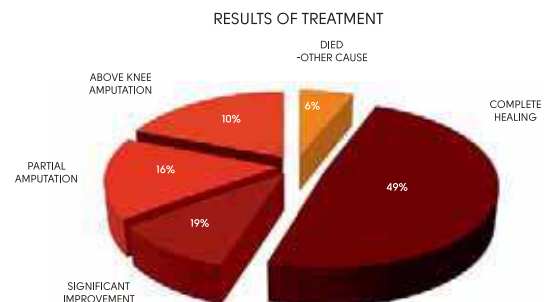
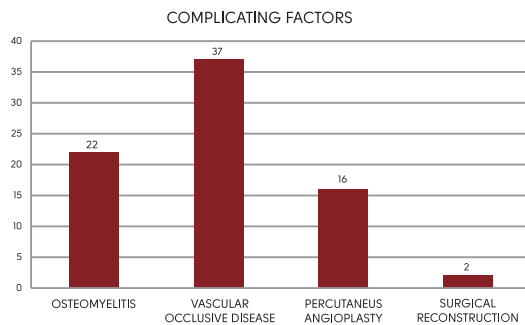
METHODS

Our study was completed within the years between 2004 and 2005. All patients with severe foot defects were admitted to our specialist ward. The degree of vascular occlusion was assessed and recorded. Diagnosis of osteomyelitis was confirmed or excluded on x-ray. Microbial culture and sensitivity was undertaken and recorded for all foot ulcers. All patients with osteomyelitis received systemic antibiotic therapy. Angioplasty was provided in patients with arterial occlusion appropriate for this therapy. All defects were treated with hyaluronan-iodine complex.

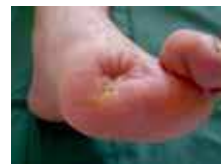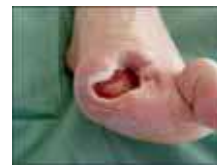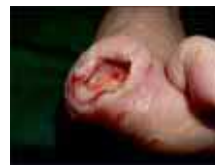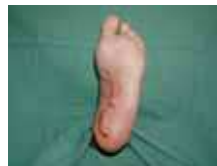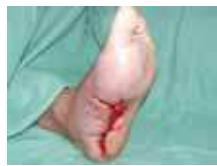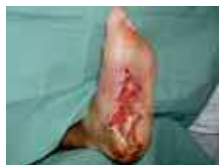RESULTS

Sixty three diabetic patients were enrolled in our study, 22 patients had osteomyelitis (Wagner III) and 37 patients occlusive vascular disease. All patients with osteomyelitis were treated with systemic antibiotics. Percutaneous angioplasty was undertaken in 16 patients, surgical vascular reconstruction in 2 patients.

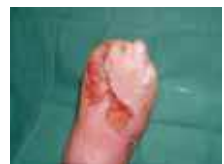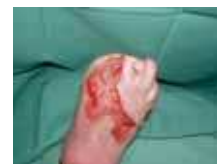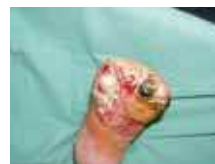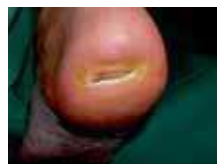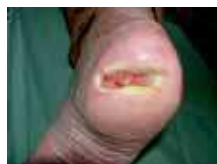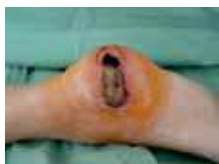Interim results - complete healing was recorded in 31 patients treated with hyaluronan-iodine complex. At the time of this report a further 12 patients were still undergoing treatment with significant improvements recorded and almost complete healing has been achieved in this group. Partial amputation was undertaken in 10 patients and above knee amputation in a further 6 patients (all with arterial occlusion). Four patients died – not related to the wound. No adverse effect of treatment was found in our study group.



COMPLETE HEALING



SIGNIFICANT IMPROVEMENT



CONCLUSION

Significant improvement in 63 diabetic patients with complex ulcers after 12 months of treatment. Our hyaluronan-iodine complex approach to the treatment of diabetic foot led to the significant improvement in healing. Hyaluronan-iodine complex was an effective and safe method for local wound treatment.

This study was supported by grant MSM0021620820 Czech Republic